




Anti-hyperglycaemic and selected organ protective effects of *Ziziphus spina-christi* hydroethanol leaf extract in alloxan induced diabetic rats

Abubakar Mohammed¹, Mohammed Adewumi Abdulrasak^{1*}, Amina Ladidi Musa², Jibril Hassan Liman¹, Ehimen Israel¹, Usman Harry¹, Ismail Ozisalami¹, Dan' Iya Usman¹, and Olatilewa Dickson¹

¹Department of Biochemistry, Federal University of Lafia, Lafia, Nasarawa State, Nigeria.

²Department of Science Laboratory Technology, Federal University of Lafia, Lafia, Nasarawa State, Nigeria.

*Correspondence: abdulrasakmohammedadewumi@gmail.com; +23408065490170

Abstract	Article History
<p><i>Ziziphus spina-christi</i> has been traditionally used for the treatment of stomach pain, wounds, and hair loss, skin infections, diarrhoea, scorpion stings, and malaria. This study aims to investigate the anti-hyperglycaemic, anti-dyslipidaemic, liver and kidney protective effects of <i>Ziziphus spina-christi</i> ethanol leaf extract on diabetic rats. The experimental design comprises of five groups of albinos Wistar rats, with three rats per group. They are normal control group, normal and 150mg/kg bwt treatment with extract group, diabetic control group, diabetic and treatment with the 150mg/kg bwt extract group, and diabetic treated with Metformin as standard drug treated for 14 days. The results of the study indicated that there was a significant ($P<0.05$) reduction in the blood glucose level in the extract and reference drug administered groups as compared to the diabetic control. The levels of the serum alanine transaminase, serum aspartate transaminase and serum alkaline phosphatase activities were significantly ($P<0.05$) lower in the extract and standard drug treatment groups compared to the diabetic control group. In the diabetic control group, the creatinine and urea concentrations were significantly ($P<0.05$) higher compared with the extract and metformin treated groups. Also, the high-density lipoprotein and triacylglycerol levels were lower in the extract treated groups demonstrating a good lipid profile. In conclusion, <i>Ziziphus spina-christi</i> exhibits anti-hyperglycaemia, anti-dyslipidaemia and liver and kidney protective activities in diabetic model, and thus supporting its traditional usage in diabetes management.</p>	<p>Received: 29/05/2023 Accepted: 06/07/2023 Published: 26/08/2023</p>
<p>How to cite this paper: Mohammed, A., Abdulrasak, MA., Musa, AL., Liman, JH., Israel, E., Harry, U., Ozisalami, I., Usman, D. and Dickson O. (2023). Anti-hyperglycaemic, liver and kidney protective effects of <i>Ziziphus spina-christi</i> ethanol extract in alloxan induced diabetic rats. <i>Gadau J Pure Alli Sci</i>, 2(2): 146-155. https://doi.org/10.54117/gjpas.v2i2.102.</p>	<p>Keywords <i>Ziziphus spina-christi</i>; Anti-hyperglycaemic; Hepatoprotective; Renal protective; Lipid profile; Anti-dyslipidaemia</p> <p>License: CC BY 4.0*</p>  <p>Open Access Article</p>

1.0 Introduction

Diabetes mellitus (DM) is a metabolic disease characterized by persistent high level of glucose concentration (hyperglycaemia) in the blood stream resulting from defects in insulin secretion, insulin action, or as a result of both anomaly (Harreiter and Roden, 2019; Petersmann *et al.*, 2019). The inefficient or lack of action of insulin on skeletal muscle, adipose and hepatic tissues prelude the perturbation in carbohydrate, lipids, and protein metabolism in DM patients. The resultant elevated sugar level leads to complications experienced by DM patients which

brings harm to different organs of the body, mainly the eyes, kidneys, nerves, blood vessels and sexual dysfunction which directly impact on the quality of life and overall life expectancy (Curran *et al.*, 2023; Deshmukh *et al.*, 2015; Faselis *et al.*, 2019; Soumya and Srilatha, 2011).

Several anti-diabetic drugs are currently available for treatment of hyperglycaemia. However, the use of most these drugs to lower blood glucose induces side effects like lactic acidosis, dizziness, severe hypoglycaemia, digestive discomfort, idiosyncratic liver cell injury, permanent neurological deficit,

headache, weight gain, oedema, anaemia, and swelling of legs or ankles (Hui *et al.*, 2009; Joseph and Jini, 2011; Kumar Sharma and Gupta, 2017; Watal *et al.*, 2014). The long-time aetiological nature of DM, and its attendant complications, portends diabetes to be an expensive disease to manage. Also, the management of diabetes without side effects has continue to be challenging to medical fraternity. The search for remedies for diseases since ancient times has exploited natures' biodiversity for drugs. The beginning of use of medicinal plant was instinctive just like in animals (Stojanoski, 1999).

Medicinal plants are natures' valuable reservoir of novel drugs compounds. The dependency on herbal drug regimens in developing countries is about 80% for their primary healthcare and over 25% of prescription orthodox medications are developed from compounds found in plants (Hamilton, 2004). Furthermore, a large number of recent nutraceuticals, nutritional supplements, and medications are based on their phytochemical compositions (Abdulrahman *et al.*, 2022). Moreover, they seem to cost less with minimal or no side effects, thereby attracting many healthcare professionals. There is a decreasing efficacy and increasing complications of synthetic drugs usage, so making the use of natural drugs relevant again, and as such, there is need for further investigation into these medicinal plants (Petrovska, 2012).

Ziziphus spina-christi (ZS) which is called Christ's thorn Jujube, is a deciduous tree that is natively grown in the warm-temperate and subtropical regions of the globe, including North Africa, Mediterranean, South and East of Asia, Australia, tropical America, South Europe, and Middle East (Asgarpanah and Haghighat, 2012; Yossef *et al.*, 2011). It is a member of the *Rhamnaceae* family belonging to the order Rosales. *Ziziphus spina-christi* is indigenous and naturalized throughout Iran as it is an important constituent of traditional medicine (Solati and Soleimani, 2010). The Iranians called it "Sidr" (Salehi MH, 2010). The various parts of the plant such as the leaf, root, stem and flower have been used traditionally across the globe for treatment of stomach pain, dandruff, wounds, and hair loss, skin infections, constipation, Cough, diarrhoea, rheumatism, scorpion stings, malaria, and antispasmodics (Abdulrahman *et al.*, 2022; Alalwan *et al.*, 2019; Auda, 2011; Delfan *et al.*, 2015; El-Kamali and El-Khalifa, 1999; Madani *et al.*, 2021; Musa *et al.*, 2011; Tetik *et al.*, 2013). It reaches around 20m in height with a diameter of about 60cm. It has a light-grey, cracked, and scaly bark with twisted and branched trunk. Also, the thorns are in pairs, with one straight, and the other curved. Its leaves are glabrous on upper surface, finely pubescent below, ovate-lanceolate or ellipsoid, apex acute or obtuse, margins almost entire, lateral veins conspicuous. Its

fruit is about 1cm in diameter (Asgarpanah and Haghighat, 2012). The fruits are very nutritious fruits and usually eaten fresh and the flowers serve as important source of nectar to honey bees in Yemen and Eritrea (Adzu and Haruna, 2010). The fruit is used for treating pulmonary ailments, fevers, promote the wound and ulcer healing, and dysentery (Abalaka *et al.*, 2010). *Ziziphus spina-christi* (Sidr) is rich in carbohydrates (glucose, galactose, fructose, and starch), protein, fat, organic acids (citric, malonic, and malic acid), minerals (calcium, iron, potassium, and magnesium), vitamins (thiamin, riboflavin, niacin, and ascorbic acid) and carotene (Aldhanhani *et al.*, 2022). Previous studies have identified phytochemical composition of *Ziziphus spina-christi*, which include geranyl acetate, sterols (such as β -sitosterol), triterpenoid sapogenins, saponins, (such as betulinic acid), methyl hexadecanoate, peptide and cyclopeptide alkaloids (such as spinanine-A), flavonoids (such as rutin and quercetin derivatives), methyl octadecanoate, tanins, and triterpenoid sapogenins, (Almeer *et al.*, 2018; Jafarian *et al.*, 2014).

There are report of the use of the leaves for the treatment of ulcer, inflammatory, hypertensive, hypoglycemia, and fungal diseases. The leaves are also hepatoprotective, antioxidant, antitumor, antimicrobial, and immune system modulatory agents in folk medicine (Almeer *et al.*, 2018; Dkhil *et al.*, 2018; Guizani *et al.*, 2013; Jafarian *et al.*, 2014). This research sought to investigate the effects of the ethanol extract of *Ziziphus spina-christi* leaf on anti-hyperglycemic, liver and kidney protective, and anti-hyperlipidemic activities in alloxan induced diabetic rats.

2.0 Materials and Methods

2.1 Chemicals

The chemicals used in this study were of analytical grade. Randox Laboratory limited, UK, kits were purchased from reputable vendors for liver function, kidney function, and lipid profile assays.

2.2 Extraction Procedure

The leaves of *Ziziphus spina-christi* were purchased from the market in Lafia metropolis. The leaves were identified at the department of Plant Science and Biotechnology, Federal University of Lafia, Lafia, Nasarawa State, Nigeria, air dried under shade to constant weight, grind into powder and stored at in an airtight container until needed. Fifty grams (50 g) of the powdered *Ziziphus spina-christi* leaves was dissolved in 250ml of 50% ethanol solvent in a sterile bottle and shaken vigorously at intervals. The mixture was left to stand overnight for 48 hours at room temperature. The mixture was then filtered using a clean muslin cloth and then with Whatman No.1 filters paper. The hydroethanol extraction filtrate was then evaporated on a water bath at 45°C. The resulting

slurry was weighed, stored at 4 °C and reconstituted with distilled water at required dose for animal treatment.

2.3 Experimental design and animal handling

Fifteen (15) Male albino Wistar rats (*Rattus norvegicus*) were obtained from the animal holding unit of the veterinary institute Vom, Jos, Plateau state, Nigeria. The animals acclimatized for a period of seven (7) days. The rats were divided into 5 groups of 3 rats each and housed in a wooden cage. The animal maintained at room temperature in a well-ventilated animal house with 12 hours of natural light- dark cycle. The animal had free access to food and water *ad libitum*. Proper care and handling were observed and periodic cleaning and removal of faeces and spilled feeds from cages. Compliance with the guide for the care and use of laboratory animals in accordance with good laboratory practice (GLP) regulations of the World Health Organization (WHO) was duly followed.

Group 1: Normal Control

Group 2: Diabetic Control

Group 3: Diabetic with metformin (150mg/kg bwt)

Group 4: Diabetic with *Ziziphus spina-christi* leaf extract (150mg/kg bwt)

Group 5: Normal with *Ziziphus spina-christi* leaf extract (150mg/kg bwt)

Group 4 and Group 5 were used to investigate the therapeutic effect and the toxicity effect of extract treatment respectively. During the acclimatization for a week, the rats were fed normal animal chow and water twice daily. Diabetes mellitus was intraperitoneally induced in albino Wistar rats. Alloxan was dissolved in distilled water and administered at a single dose of 150 mg/kg body weight after an overnight fast for 11-12 hours. Diabetes was confirmed by the elevation of blood glucose levels to 300 mg/dl after 72 hours using Accu-check glucometer. The treatments were administered for a 14 days period through oral gavage. The fasting blood glucose and body weight was measured twice weekly.

2.4 Biochemical analysis

2.4.1 Determination of liver function markers

Serum activities of Alanine Amino Transferase (ALT) and Aspartate amino Transferases (AST) were assayed for by monitoring the concentration of the pyruvate hydrazone complex formed upon reactions with 2,4-dinitrophenylhydrazine and oxaloacetate hydrazone complex formed upon reactions with 2,4-dinitrophenylhydrazine as specified by Reitman and Frankel (1957) respectively.

2.4.2 Determination of Kidney function markers

In an alkaline solution creatinine reacts with Picric acid to form a red coloured complex. Urea was measured based on the principle of urease enzyme hydrolysing urea to ammonia and carbon dioxide. The

ammonia then reacts with alkaline hydrochloride and sodium salicylate in the presence of sodium nitroprusside to form a coloured chromophore as described by Kassirer (1971)

2.4.3 Determination of markers of lipid profile

Total serum cholesterol, total triacylglycerol and high-density lipoprotein cholesterol concentrations are estimated as specified in the Randox kit.

2.5 Statistical Analysis

All results were represented as mean \pm standard deviation (SD). Data were analysed using one way analysis of variance (ANOVA) followed by Tukey post hoc to find significant pairs. A *P*-value of less than 0.05 was considered statistically significant. GraphPad Prism version 5 (GraphPad software, Inc., USA) software was used for the analysis.

3.0 Results

3.1 Experimental animal change in Body Weight

The body weights (g) of all treatment group of rats are presented below in Figure 1. All the groups appreciably gained weight except the diabetic control (DC) group.

3.2 Experimental animal change in Blood Glucose

The level of the blood glucose concentration (mmol/L) of all test groups is presented in Figure 2. The trend of the blood glucose level of the diabetic control (DC) group was markedly elevated.

3.3 Activities of Liver Function Biomarkers

The mean AST activity in the serum of all rats belonging to the five groups, denoting the functioning status of the liver is presented in Figure 3. The three treatment groups showed a significant (*P*<0.05) reduced AST activity compared to the DC group. The mean ALT activity in the serum of all rats belonging to the five groups, depicting the functioning status of the liver is presented below in Figure 4. The three treatment groups showed a significant (*P*<0.05) reduced ALT activity compared to the DC group.

3.4 Activities of Kidney Function Biomarkers

The mean concentration of the serum urea per group is presented in Figure 5. The treatment groups showed a significant (*P*<0.05) reduced urea concentration compared to the DC group. Mean creatinine concentrations of the rats in all five groups for measuring the kidney functioning presented in Figure 6. The treatment groups showed a significant (*P*<0.05) reduced creatinine concentration compared to the DC group.

3.5 Concentration of Lipid Profile Biomarkers

The concentration of total cholesterol of rats in the groups are presented in Figure 7. The total was significantly (*P*<0.05) higher compared to the other groups.

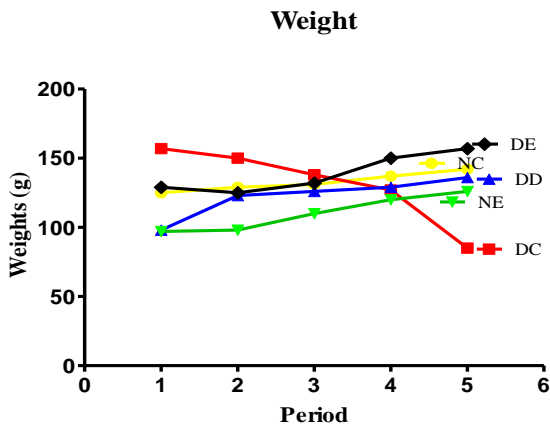


Figure 1: Weight of experimental animal treated with hydroethanol extract of *Ziziphusspina-christi* leaf for 14 days. NC= Normal Control, DC= Diabetic Control, DD= Diabetic with metformin (150mg/kg), DE= Diabetic with *Ziziphusspina-christi* leaf extract (150mg/kg), NE=Normal with *Ziziphusspina-christi* leaf extract (150mg/kg)

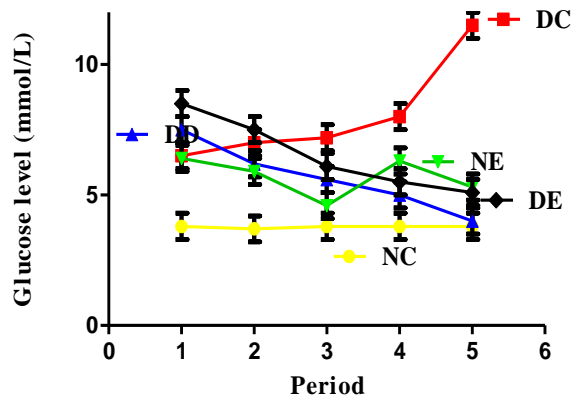


Figure 2: Blood glucose level of experimental animal treated with hydroethanol extract of *Ziziphusspina-christi* leaf for 14 days. NC= Normal Control, DC= Diabetic Control, DD= Diabetic with metformin (150mg/kg), DE= Diabetic with *Ziziphusspina-christi* leaf extract (150mg/kg), NE=Normal with *Ziziphusspina-christi* leaf extract (150mg/kg)

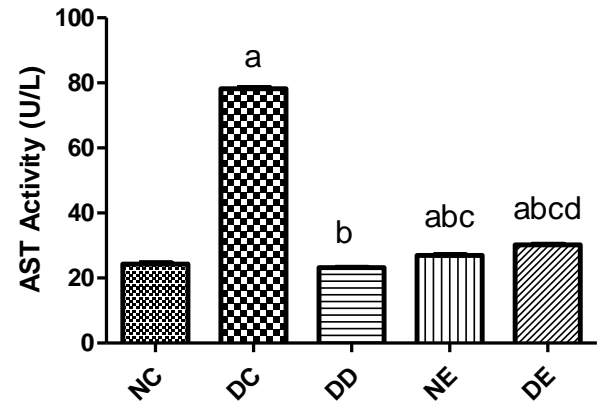


Figure 3: Serum aspartate aminotransferase activities in experimental animals treated with hydroethanol extract of *Ziziphusspina-christi* leaf for 14 days. NC= Normal Control, DC= Diabetic Control, DD= Diabetic with metformin (150mg/kg), DE= Diabetic with *Ziziphusspina-christi* leaf extract (150mg/kg), NE=Normal with *Ziziphusspina-christi* leaf extract (150mg/kg).

Each of the alphabet a,b,c, and d on the bars denotes statistical significance when the group was compared with NC, DC, DD, and NE groups respectively.

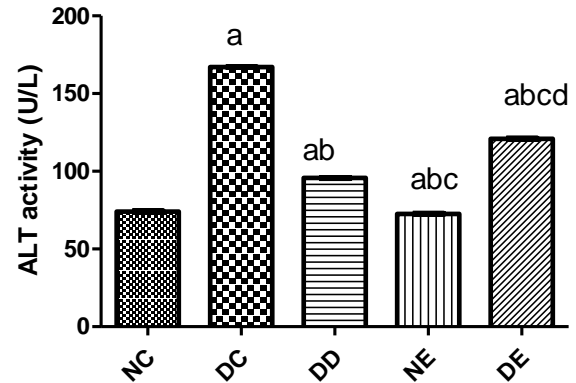


Figure 4: Alanine aminotransferase activities in experimental animals treated with hydroethanol extract of *Ziziphusspina-christi* leaf for 14 days. NC= Normal Control, DC= Diabetic Control, DD= Diabetic with metformin (150mg/kg), DE= Diabetic with *Ziziphusspina-christi* leaf extract (150mg/kg), NE=Normal with *Ziziphusspina-christi* leaf extract (150mg/kg).

Each of the alphabet a,b,c, and d on the bars denotes statistical significance when the group was compared with NC, DC, DD, and NE groups respectively.

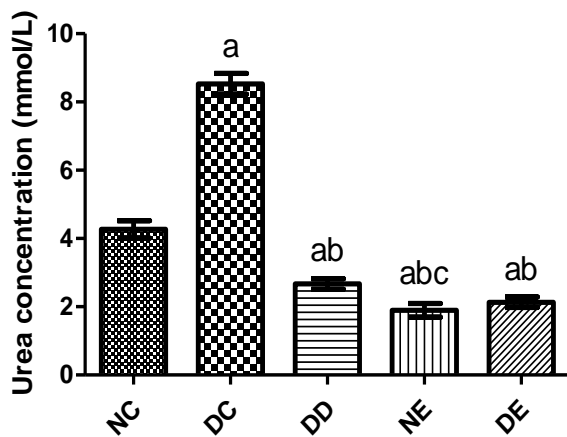


Figure 5: Serum Urea concentration in experimental animals treated with hydroethanol extract of *Ziziphusspina-christi* leaf for 14 days. NC= Normal Control, DC= Diabetic Control, DD= Diabetic with metformin (150mg/kg), DE= Diabetic with *Ziziphusspina-christi* leaf extract (150mg/kg), NE=Normal with *Ziziphusspina-christi* leaf extract (150mg/kg). Each of the alphabet a,b, and c on the bars denotes statistical significance when the group was compared with NC, DC, and DD groups respectively.

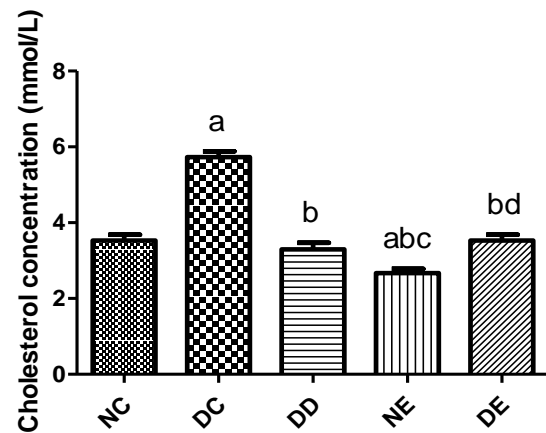


Figure 7: Total Cholesterol concentration in experimental animals treated with hydroethanol extract of *Ziziphusspina-christi* leaf for 14 days. NC= Normal Control, DC= Diabetic Control, DD= Diabetic with metformin (150mg/kg), DE= Diabetic with *Ziziphusspina-christi* leaf extract (150mg/kg), NE=Normal with *Ziziphusspina-christi* leaf extract (150mg/kg). Each of the alphabet a,b,c, and d on the bars denotes statistical significance when the group was compared with NC, DC, DD, and NE groups respectively.

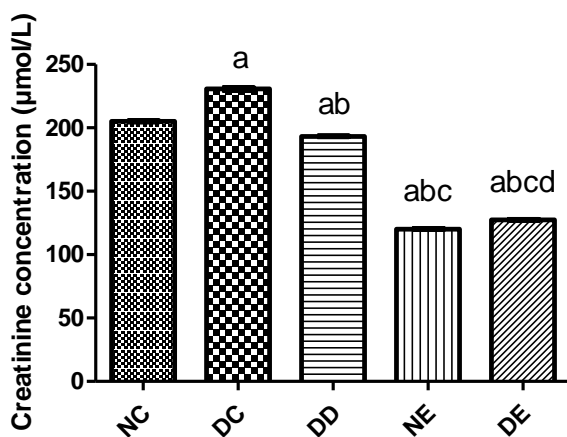


Figure 6 Serum Creatinine concentration in experimental animals treated with hydroethanol extract of *Ziziphusspina-christi* leaf for 14 days. NC= Normal Control, DC= Diabetic Control, DD= Diabetic with metformin (150mg/kg), DE= Diabetic with *Ziziphusspina-christi* leaf extract (150mg/kg), NE=Normal with *Ziziphusspina-christi* leaf extract (150mg/kg). Each of the alphabet a,b,c, and d on the bars denotes statistical significance when the group was compared with NC, DC, DD, and NE groups respectively.

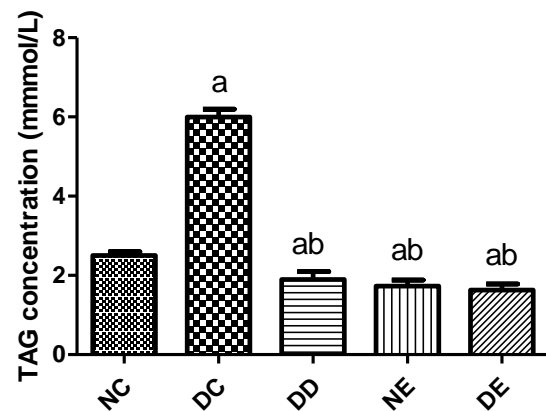


Figure 8: Triacylglycerol concentration in experimental animals treated with hydroethanol extract of *Ziziphusspina-christi* leaf for 14 days. NC= Normal Control, DC= Diabetic Control, DD= Diabetic with metformin (150mg/kg), DE= Diabetic with *Ziziphusspina-christi* leaf extract (150mg/kg), NE=Normal with *Ziziphusspina-christi* leaf extract (150mg/kg). Each of the alphabet a, and b on the bars denotes statistical significance when the group was compared with NC, and DC groups respectively.

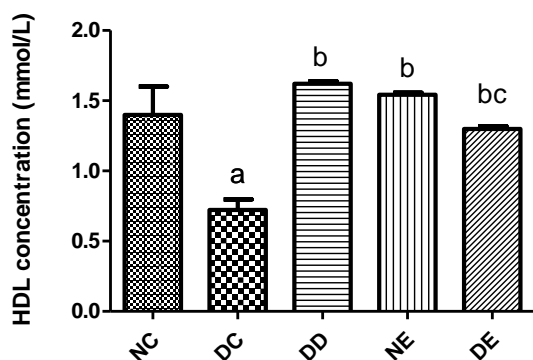


Figure 9: High density lipoprotein concentration in experimental animals treated with hydroethanol extract of *Ziziphusspina-christi* leaf for 14 days s. NC= Normal Control, DC= Diabetic Control, DD= Diabetic with metformin (150mg/kg), DE= Diabetic with *Ziziphusspina-christi* leaf extract (150mg/kg), NE=Normal with *Ziziphusspina-christi* leaf extract (150mg/kg).

Each of the alphabet a, b, and c on the bars denotes statistical significance when the group was compared with NC, DC, and DD groups respectively.

The concentration of triacylglycerol level of all rats in all groups are given in Figure 8. The treatment groups showed a significant ($P<0.05$) reduced TAG concentration compared to the DC group. The concentration of HDL (mmol/dl) of all rats in the 5 groups are presented below in Figure 9. The treatment groups showed a significant ($P<0.05$) elevated HDL concentration compared to the DC group.

4.0 Discussion

The present results revealed that body weight trend over the experimentation period for the diabetic control group was lower than that of normal control group as shown in Figure 1. The loss of weight may be associated to dehydration, hyperglycemia, insulin deficiency or resistance, increased glycogenolysis, lipolysis, gluconeogenesis which culminates in muscles wasting and loss of tissue protein (Ewenighi *et al.*, 2015). Viridi *et al.* (2003) explained that diabetics experience dehydration and high rate of breakdown of fats and proteins due to carbohydrates unavailability as cellular source of energy. Since the mechanism of action of metformin improves insulin sensitivity, there was increase in the diabetic rats' body weight in the present study. However, its lowering effect on food and caloric consumption has been confirmed by Lee and Morley (Lee and Morley, 1998). So, this may account for the lower weight gain effect compared to those of the *Ziziphus spina-christi* leaf extract group. These effects coupled with their potency in healing loss of appetite (Abalaka *et al.*,

2010; Ghafoor *et al.*, 2012; Yossef *et al.*, 2011) and possibility of directly stimulating the direct uptake of glucose into the peripheral tissues may account for the treatment ameliorating effects on body weight of the diabetic rats in this study.

The major clinical manifestations of diabetes mellitus which is hyperglycaemia was observed in the experimental animal after alloxan administration. This is consistent with documentations of other researchers, stating that alloxan causes cytotoxic effect on β -cells of the pancreas, presenting characteristics of type 1 diabetes mellitus (Lenzen *et al.*, 1996). Szkudelski, (2001) described alloxan mechanism of cytotoxicity to involve oxidation of important sulphhydryl (-SH) group in the pancreatic β -cells, glucokinase inhibition, production of free radicals and disruption of calcium ion homeostasis. This ultimately results in the reduced insulin secretion, and the attendant hyperglycemia, metabolic derangement and other related diabetic pathology. The anti-hyperglycaemic effect of *Ziziphus spina-christi* leaf extract and metformin noticed in the present study may be attributed to improvement in peripheral sensitivity to insulin. Insulin stimulates the cellular uptake of glucose in the muscle and decreases glucose production in the liver. Furthermore, reports have shown metformin alleviates oxidative stress, inhibition of glucose absorption in the small intestine and restores inflammatory markers in diabetic patients (Chakraborty and Hancz, 2011; Davidson and Peters, 1997).

Our result showed that aqueous extract of *Ziziphus spina-christi* leaf procured from Lafia was able to reverse the hyperglycemia as revealed in Figure 2 which is in agreement with those of previous studies that demonstrated that the plant extracts and fractions are able to ameliorate hyperglycaemia in rats (Abdel-Zaher *et al.*, 2005; Al-Ghamdi and Shahat, 2018).

The anti-diabetic effect of *Ziziphus spina-christi* as reported by Niamat *et al.* (2012) may be attributed to presence of secondary metabolites which includes phenolics, alkaloids, flavonoids, terpenoids and glycosides present in *Z. spina-christi*. The hypoglycemic and hyper-insulinemic effects of Christinin-A, which is a major saponin glycoside found in Sidr was reported as some other studies on *Ziziphus spina-christi* revealed increased C-peptide levels, activities of glucose-6-phosphate dehydrogenase and decrease of hepatic glucose-6-phosphatase, α -glucosidase and α -amylase activities (Adzu *et al.*, 2002; Al-Ghamdi *et al.*, 2021; Elbashir *et al.*, 2018; Michel *et al.*, 2011). The anti-hyperglycaemic activity of ZC may also be attributed to scavenging of free radical as shown in the study of Elbashir *et al.* (2018). They showed in their study on eighteen Sudanese medicinal plants, that *Ziziphus spina-christi* 70% ethanol extract was more potent compared to

aqueous extract towards inhibition of α -glucosidase activity and scavenging of free radicals.

The increased activities of serum AST and ALT is mainly due to their leakage from the liver cytosol into the blood stream which suggest probable hepatotoxic effect of alloxan (Concepcion Navarro *et al.*, 1993). This may result from failure in elimination of metabolic end products of proteins because in diabetics, the rate of protein metabolism is increased as a result of increased rate of gluconeogenesis (Guyton and Hall, 2000). The liver function markers of AST, and ALT activities (Figure 3 and 4) were significantly lowered by the *Ziziphus* aqueous extract treatment. Corroboratively, it was found that serum urea and creatinine concentrations were elevated in the diabetic group and lowered by the *Ziziphus* aqueous extract treatment (Figure 5 and 6). Serum urea and creatinine concentrations are considered as significant biomarkers of renal dysfunction (Almdal and Vilstrup, 1988). Okasha *et al.* (2017) suggested the slight reduction in renal damage induced in Ehrlich Ascites Carcinoma load in experimental animals was because of the Sidr leaf extract addition. The toxic effect of alloxan on hepatic and renal function biomarkers, in this study, are in tandem with Khadre *et al.* (2011). This study result is consistent with the work of Al-Ghamdi *et al.* (2021) which demonstrated the hepatoprotective and nephroprotective capabilities of the methanol extract and aqueous fraction in a dose dependent manner in rats intoxicated with carbon tetrachloride. The renal ameliorative effects in the present study may be because of the antioxidant potential of the ZC leaves.

The anti-dyslipidaemia effect of metformin, in the present study, figure 7 and 8, is in agreement to that of Zhang *et al.* (2017) which implied that metformin may ameliorate symptoms of diabetic nephropathy through the modulation of lipid metabolism. Metformin may mechanistically reduce the rate of lipolysis which in essence reduces the hepatic turnover rate of free fatty acids conversion to lipoprotein precursors (Han and Kaufman, 2016; Melmed *et al.*, 2016). On the other hand, *Ziziphus* extract also showed hypolipidemic effects. Furthermore, the anti-dyslipidemia effect of this study is consistent with the works of Othman *et al.*, (2009) and Parsaeyan and Rezvani, (2014). Anti-dyslipidemia effect has been associated with the presence of saponins because they form an insoluble complex with cholesterol and increase faecal lipid excretion (Zhao *et al.*, 2005). Also, saponins increase liver LDL receptor activity and also decrease synthesis of triglycerides (Yugarani *et al.*, 1992).

Diabetes mellitus (DM) is a metabolic disorder characterise by the clinical presentation of persistent high blood glucose level known as hyperglycaemia. The attendant toxicity of the current drugs in use for the management of DM, and their prolong use has

called for the search of new drugs with lesser toxicity and a curative solution. Plants are important source of drug candidates and leads from nature. *Ziziphus spina christi*, has been used in folklore medicine in Nigeria to treat several medical conditions including diabetes. The finding of our result validates its use for diabetic treatment as it possesses ability to lower high blood glucose, ameliorate liver and kidney damage, and improve the lipid profile.

5.0 Conclusion

The present study demonstrated that hydroethanol extract of *Ziziphus spina-christi* leaves possesses anti-hyperglycaemic, anti-dyslipidaemia, liver and kidney protective activities. Further studies on understanding of the mechanisms of the phytochemicals of *Ziziphus spina-christi* in treatment of diabetes is required.

Declarations

Ethics approval and consent to participate

Not Applicable

Consent for publication

All authors have read and consented to the submission of the manuscript.

Availability of data and material

Not Applicable.

Competing interests

All authors declare no competing interests.

Funding

There was no funding for the current report.

References

- Abalaka, M. E., Daniyan, S. Y., and Mann, A. (2010). Evaluation of the antimicrobial activities of two *Ziziphus* species (*Ziziphus mauritiana* L. and *Ziziphus spinachristi* L.) on some microbial pathogens. *African Journal of Pharmacy and Pharmacology*, 4(4), 135–139. <https://doi.org/10.5897/ajpp.9000150>
- Abdel-Zaher, A. O., Salim, S. Y., Assaf, M. H., and Abdel-Hady, R. H. (2005). Antidiabetic activity and toxicity of *Ziziphus spina-christi* leaves. *Journal of Ethnopharmacology*, 101(1–3), 129–138.
- Abdulrahman, M. D., Zakariya, A. M., Hama, H. A., Hamad, S. W., Al-Rawi, S. S., Bradosty, S. W., and Ibrahim, A. H. (2022). Ethnopharmacology, Biological Evaluation, and Chemical Composition of *Ziziphus spina-christi* (L.) Desf.: A Review. *Advances in Pharmacological and Pharmaceutical Sciences*, 2022. <https://doi.org/10.1155/2022/4495688>
- Adzu, B., Amos, S., Dzarma, S., Wambebe, C., and Gamaniel, K. (2002). Effect of *Ziziphus spina-christi* Willd aqueous extract on the central nervous system in mice. *Journal of*

- Ethnopharmacology*, 79(1), 13–16. [https://doi.org/10.1016/S0378-8741\(01\)00348-8](https://doi.org/10.1016/S0378-8741(01)00348-8)
- Adzu, B., and Haruna, A. (2010). Studies on the use of *Zizyphus spina-christi* against pain in rats and mice. *African Journal of Biotechnology*, 6(11). <https://doi.org/10.4314/ajb.v6i11.57480>
- Alalwan, T. A., Alkhuzai, J. A., Jameel, Z., and Mandeel, Q. A. (2019). Quantitative Ethnobotanical Study of some Medicinal Plants used by Herbalists in Bahrain. *Journal of Herbal Medicine*, 17–18, 100278. <https://doi.org/10.1016/j.hermed.2019.100278>
- Aldhanhani, A. R. H., Ahmed, Z. F. R., Tzortzakakis, N., and Singh, Z. (2022). Maturity stage at harvest influences antioxidant phytochemicals and antibacterial activity of jujube fruit (*Ziziphus mauritiana* Lamk. and *Ziziphus spina-christi* L.). *Annals of Agricultural Sciences*, 67(2), 196–203. <https://doi.org/10.1016/J.AOAS.2022.12.003>
- Al-Ghamdi, A. A. M., El-Zohri, M., and Shahat, A. A. (2021). Hepatoprotective, nephroprotective, anti-amylase, and antiglycosidase effects of *Ziziphus spina-christi* (L.) against carbon tetrachloride-induced toxicity in rats. *Tropical Journal of Pharmaceutical Research*, 18(4), 781–790. <https://doi.org/10.4314/tjpr.v18i4.15>
- Al-Ghamdi, A. A. M., and Shahat, A. A. (2018). Antioxidant, hypoglycemic and anti-diabetic activities of *Ziziphus spina-christi* (L.) Willd (Rhamnaceae) leaf extract. *Tropical Journal of Pharmaceutical Research*, 16(11), 2601–2610. <https://doi.org/10.4314/tjpr.v16i11.5>
- Almdal, T. P., and Vilstrup, H. (1988). Strict insulin therapy normalises organ nitrogen contents and the capacity of urea nitrogen synthesis in experimental diabetes in rats. *Diabetologia*, 31(2), 114–118. <https://doi.org/10.1007/BF00395558>
- Almeer, R. S., Mahmoud, S. M., Amin, H. K., and Abdel Moneim, A. E. (2018). *Ziziphus spina-christi* fruit extract suppresses oxidative stress and p38 MAPK expression in ulcerative colitis in rats via induction of Nrf2 and HO-1 expression. *Food and Chemical Toxicology*, 115, 49–62. <https://doi.org/10.1016/J.FCT.2018.03.002>
- Asgarpanah, J., and Haghghat, E. (2012). Phytochemistry and pharmacologic properties of *Ziziphus spina christi* (L.) Willd. *African Journal of Pharmacy and Pharmacology*, 6(31), 2332–2339. <https://doi.org/10.5897/AJPP12.509>
- Auda, M. A. (2011). An Ethnobotanical uses of Plants in the Middle Area, Gaza Strip, Palestine. *Advances in Environmental Biology*, 5(11), 3681–3687.
- Chakraborty, S. B., and Hancz, C. (2011). Application of phytochemicals as immunostimulant, antipathogenic and antistress agents in finfish culture. *Reviews in Aquaculture*, 3(3), 103–119. <https://doi.org/10.1111/j.1753-5131.2011.01048.x>
- Concepcion Navarro, M., Montilla, M. P., Martin, A., Jimenez, J., and Utrilla, M. P. (1993). Free radical scavenger and antihepatotoxic activity of *Rosmarinus tomentosus*. *Planta Medica*, 59(4), 312–314. <https://doi.org/10.1055/S-2006-959688/BIB>
- Curran, K., Piyasena, P., Congdon, N., Duke, L., Malanda, B., and Peto, T. (2023). Inclusion of diabetic retinopathy screening strategies in national-level diabetes care planning in low- and middle-income countries: a scoping review. *Health Research Policy and Systems* 2022 21:1, 21(1), 1–11. <https://doi.org/10.1186/S12961-022-00940-0>
- Davidson, M. B., and Peters, A. L. (1997). An Overview of Metformin in the Treatment of Type 2 Diabetes Mellitus. *The American Journal of Medicine*, 102(1), 99–110. [https://doi.org/10.1016/S0002-9343\(96\)00353-1](https://doi.org/10.1016/S0002-9343(96)00353-1)
- Delfan, B., Bahmani, M., Hassanzadazar, H., Saki, K., Rafieian-Kopaei, M., Rashidipour, M., Bagheri, F., Sharifi, A., Researchers, Y., and Club, E. (2015). Ethnobotany study of effective medicinal plants on gastric problems in Lorestan province, West of Iran. *Journal of Chemical and Pharmaceutical Research*, 7(2), 483–492. www.jocpr.com
- Deshmukh, C. D., Jain, A., Deshmukh, C. D., and Jain, A. (2015). Diabetes Mellitus: A Review. *International Journal of Pure and Applied Bioscience*, 3(3), 224–230.
- Dkhal, M. A., Al-Quraishy, S., and Moneim, A. E. A. (2018). *Ziziphus spina-christi* leaf extract pretreatment inhibits liver and spleen injury in a mouse model of sepsis via anti-oxidant and anti-inflammatory effects. *Inflammopharmacology*, 26(3), 779–791. <https://doi.org/10.1007/S10787-017-0439-8/METRICAL>
- Elbashir, S. M. I., Devkota, H. P., Wada, M., Kishimoto, N., Moriuchi, M., Shuto, T., Misumi, S., Kai, H., and Watanabe, T. (2018). Free radical scavenging, α -glucosidase inhibitory and lipase inhibitory activities of eighteen Sudanese medicinal plants. *BMC Complementary and Alternative Medicine*, 18(1). <https://doi.org/10.1186/S12906-018-2346-Y>

- El-Kamali, H. H., and El-Khalifa, K. F. (1999). Folk medicinal plants of riverside forests of the Southern Blue Nile district, Sudan. *Fitoterapia*, 70(5), 493–497. [https://doi.org/10.1016/S0367-326X\(99\)00073-8](https://doi.org/10.1016/S0367-326X(99)00073-8)
- Ewenighi, C., Dimkpa, U., Onyeanusi, J., Onoh, L., Onoh, G., and Ezeugwu, U. (2015). Estimation of glucose level and body weight in alloxan induced diabetic rat treated with aqueous extract of Garcinia Kola seed. *Ulutas Medical Journal*, 1(2), 26–30. <https://doi.org/DOI:10.5455/umj.20150507042420>
- Faselis, C., Katsimardou, A., Imprialos, K., Deligkaris, P., Kallistratos, M., and Dimitriadis, K. (2019). Microvascular Complications of Type 2 Diabetes Mellitus. *Current Vascular Pharmacology*, 18(2), 117–124. <https://doi.org/10.2174/1570161117666190502103733>
- Ghafoor, A. O., Qadir, H. K., and Fakhri, N. A. (2012). Analysis of phenolic compounds in extracts of *Ziziphus spina-christi* using RPHPLC method. *Journal of Chemical and Pharmaceutical Research*, 4(6), 3158–3163.
- Guizani, N., Waly, M. I., Singh, V., and Rahman, M. S. (2013). Nabag (*Zizyphus spina-christi*) extract prevents aberrant crypt foci development in colons of azoxymethane-treated rats by abrogating oxidative stress and inducing apoptosis. *Asian Pacific Journal of Cancer Prevention*, 14(9), 5031–5035. <https://doi.org/10.7314/APJCP.2013.14.9.5031>
- Guyton, C. A., and Hall, J. E. (2000). Insulin, glucagon and diabetes mellitus. In *Guyton and Hall Textbook of Medical Physiology* (10th Edition). W. B. Saunders Company.
- Hamilton, A. C. (2004). Medicinal plants, conservation and livelihoods. *Biodiversity and Conservation*, 13(8), 1477–1517. <https://doi.org/10.1023/B:BIOC.0000021333.23413.42>
- Han, J., and Kaufman, R. J. (2016). The role of ER stress in lipid metabolism and lipotoxicity. *Journal of Lipid Research*, 57(8), 1329–1338.
- Harreiter, J., and Roden, M. (2019). Diabetes mellitus—Definition, classification, diagnosis, screening and prevention (Update 2019). *Wiener Klinische Wochenschrift*, 131(1), 6–15. <https://doi.org/10.1007/S00508-019-1450-4/METRICS>
- Hui, H., Tang, G., and Go, V. L. W. (2009). Hypoglycemic herbs and their action mechanisms. *Chinese Medicine*, 4, 11. <https://doi.org/10.1186/1749-8546-4-11>
- Jafarian, A., Zolfaghari, B., and Shirani, K. (2014). Cytotoxicity of different extracts of arial parts of *Ziziphus spina-christi* on Hela and MDA-MB-468 tumor cells. *Advanced Biomedical Research*, 3(1), 38. <https://doi.org/10.4103/2277-9175.125727>
- Joseph, B., and Jini, D. (2011). Insight into the hypoglycaemic effect of traditional indian herbs used in the treatment of diabetes. *Research Journal of Medicinal Plant*, 5(4), 352–376.
- Kassirer, J. P. (1971). Clinical Evaluation of Kidney Function. *New England Journal of Medicine*, 285(7), 385–389. <https://doi.org/10.1056/NEJM197108122850706>
- Khadre, S. E. M., Lbrahim, H. M., Shabana, M. B., and El-Seady, N. A. A. (2011). Effect of Metformin and Glimepiride on Liver and Kidney Functions in Alloxan-Induced Diabetic Rats. *Journal of High Institute of Public Health*, 41(2), 282–310.
- Kumar Sharma, A., and Gupta, R. (2017). Anti-Hyperglycemic Activity of Aqueous Extracts of Some Medicinal Plants on Wistar Rats. *Journal of Diabetes and Metabolism*, 8. <https://doi.org/10.4172/2155-6156.1000752>
- Lee, A., and Morley, J. E. (1998). Metformin Decreases Food Consumption and Induces Weight Loss in Subjects with Obesity with Type II Non-Insulin-Dependent Diabetes. *Obesity Research*, 6(1), 47–53. <https://doi.org/10.1002/J.1550-8528.1998.TB00314.X>
- Lenzen, S., Tiedge, M., Jörns, A., and Munday, R. (1996). Alloxan derivatives as a tool for the elucidation of the mechanism of the diabetogenic action of alloxan. In *Sharper, E., (eds). Lessons from Animal Diabetes VI. Rev.Ser.Advs.Research Diab.Animals (Birkhäuser)*, (pp. 113–122). Birkhäuser Boston. https://doi.org/10.1007/978-1-4612-4112-6_8
- Madani, I., Allah Ali Ibrahim, D., and Mohamed Hamdeen, H. (2021). Abundance and Ethnomedicinal Use of Tree and Shrub Species in Azaza And Mokla Forests in the Blue Nile State, Sudan. *EPRA International Journal of Multidisciplinary Research (IJMR)*, 7(7).
- Melmed, S., Polonsky, K., Larsen, P. R., and Kronenberg, H. (2016). *Williams Textbook of Endocrinology*, 13th Edition (13th ed.). Elsevier .
- Michel, C. G., Nesseem, D. I., and Ismail, M. F. (2011). Anti-diabetic activity and stability study of the formulated leaf extract of *Zizyphus spina-christi* (L.) Willd with the influence of seasonal variation. *Journal of Ethnopharmacology*, 133(1), 53–62. <https://doi.org/10.1016/J.JEP.2010.09.001>

- Musa, M. S., Abdelrasool, F. E., Elsheikh, E. A., Ahmed, L. A. M. N., Latif, A., Mahmoud, E., and Yagi, S. M. (2011). Ethnobotanical study of medicinal plants in the Blue Nile State, South-eastern Sudan. *Journal of Medicinal Plants Research*, 5(17), 4287–4297. <http://www.academicjournals.org/JMPR>
- Niamat, R., Ajab Khan, M., Yasmin Khan, K., Ahmed, M., Mazari, P., Zafar, M., Ali, B., and Mustafa, M. (2012). A Review on Zizyphus as Antidiabetic. *Journal of Applied Pharmaceutical Science*, 2(03), 177–179.
- Okasha, S., Takadom, F., and Hassan., M. (2017). Combination effect of Zizyphus spinachristi and hyperthermia on liver and kidney affected by EAC in mice. *International Journal of Advanced Research*, 5(7), 1486–1493. <https://doi.org/10.21474/IJAR01/4861>
- Othman, A. I., Amer, M. A., Samaha, R. F., and Abdel-Mogib, M. (2009). Effects of the methanolic extracts of Zizyphus spina christi, Olea europaea and Morus alba leaves in Streptozotocin- induced diabetic rats. *The Egyptian Journal of Hospital Medicine*, 37(1), 759–771.
- Parsaeyan, N., and Rezvani, M. E. (2014). The Effect of Christ's Thorn (Zizyphus Spina Christi) Leaves Extract on Lipid Profile, Lipid Peroxidation and Liver Enzymes of Diabetic Rats. *Iranian Journal of Diabetes and Obesity*, 6(4), 163–167.
- Petersmann, A., Müller-Wieland, D., Müller, U. A., Landgraf, R., Nauck, M., Freckmann, G., Heinemann, L., and Schleicher, E. (2019). Definition, Classification and Diagnosis of Diabetes Mellitus. *Experimental and Clinical Endocrinology and Diabetes*, 127(S 01), S1–S7. <https://doi.org/10.1055/A-1018-9078/ID/R-0011>
- Petrovska, B. B. (2012). Historical review of medicinal plants' usage. *Pharmacognosy Reviews*, 6(11), 1–5.
- Reitman, S., and Frankel, S. (1957). A colorimetric method for the determination of serum glutamic oxalacetic and glutamic pyruvic transaminases. *American Journal of Clinical Pathology*, 28(1), 56–63. <https://doi.org/10.1093/AJCP/28.1.56>
- Salehi MH. (2010). *Medicinal plants and phytotherapy Vol. 3* (Vol. 3). Donya e Taghzieh Publications.
- Solati, J., and Soleimani, N. (2010). Antihyperglycemic and antihyperlipidemic effects of Zizyphus vulgaris L. on streptozotocin-induced diabetic adult male Wistar rats. *Acta Diabetologica*, 47(S1), 219–223. <https://doi.org/10.1007/s00592-009-0166-8>
- Soumya, D., and Srilatha, B. (2011). Late Stage Complications of Diabetes and Insulin Resistance. *Article in Journal of Diabetes and Metabolism*, 2, 9. <https://doi.org/10.4172/2155-6156.1000167>
- Stojanoski, N. (1999). Development of health culture in Veles and its region from the past to the end of the 20th century. *Veles: Society of Science and Art*, 13, 34–34.
- Szkudelski, T. (2001). The Mechanism of Alloxan and Streptozotocin Action in B Cells of the Rat Pancreas. *Physiological Research*, 50, 536–546.
- Tetik, F., Civelek, S., and Cakilcioglu, U. (2013). Traditional uses of some medicinal plants in Malatya (Turkey). *Journal of Ethnopharmacology*, 146(1), 331–346. <https://doi.org/10.1016/J.JEP.2012.12.054>
- Virdi, J., Sivakami, S., Shahani, S., Suthar, A. C., Banavalikar, M. M., and Biyani, M. K. (2003). Antihyperglycemic effects of three extracts from Momordica charantia. *Journal of Ethnopharmacology*, 88(1), 107–111. [https://doi.org/10.1016/S0378-8741\(03\)00184-3](https://doi.org/10.1016/S0378-8741(03)00184-3)
- Watal, G., Dhar, P., Srivastava, S. K., and Sharma, B. (2014). Herbal Medicine as an Alternative Medicine for Treating Diabetes: The Global Burden. *Evidence-Based Complementary and Alternative Medicine*, 2014. <https://doi.org/10.1155/2014/596071>
- Yossef, H. E.-D. E.-D., Khedr, A. A., and Mahran, M. Z. (2011). Hepatoprotective activity and antioxidant effects of El Nabka (Zizyphus spina-christi) fruits on rats hepatotoxicity induced by carbon tetrachloride. *Nature and Science*, 9(2), 7.
- Yugarani, T., Tan, B. K. H., Teh, M., and Das, N. P. (1992). Effects of polyphenolic natural products on the lipid profiles of rats fed high fat diets. *Lipids*, 27(3), 181–186. <https://doi.org/10.1007/BF02536175>
- Zhang, S., Xu, H., Yu, X., Wu, Y., and Sui, D. (2017). Metformin ameliorates diabetic nephropathy in a rat model of low-dose streptozotocin-induced diabetes. *Experimental and Therapeutic Medicine*, 14(1), 383–390. <https://doi.org/10.3892/ETM.2017.4475/HTML>
- Zhao, H. L., Sim, J. S., Shim, S. H., Ha, Y. W., Kang, S. S., and Kim, Y. S. (2005). Antiobese and hypolipidemic effects of platycodin saponins in diet-induced obese rats: evidences for lipase inhibition and calorie intake restriction. *International Journal of Obesity*, 29(8), 983–990. <https://doi.org/10.1038/sj.ijo.0802948>